

Cellular localization of lectin-affinity in tissue sections of normal human duodenum

K. Wurster¹, P. Peschke², and W.D. Kuhlmann²

¹ Institut für Pathologie des Städtischen Krankenhaus München-Schwabing, D-8000 München

² Labor für Experimentelle Medizin c/o Institut für Nuklearmedizin (D.K.F.Z.),
Im Neuenheimer Feld 280, D-6900 Heidelberg, Federal Republic of Germany

Summary. Peroxidase (HRP) conjugates of *Arachis hypogaea* agglutinin (PNA), *Dolichos biflorus* agglutinin (DBA), *Ulex europaeus* agglutinin I (UEA I) and *Bandeiraea simplicifolia* agglutinin I (BSA I) were used to detect the expression of carbohydrate moieties in glyco-conjugates of normal human duodenal mucosa. Lectin histology was performed on sections from paraffin embedded specimens of donor blood groups A, B, AB and O. While PNA, DBA and UEA I staining appeared to be independent of the donor blood groups, BSA I affinity was restricted to the blood groups B and AB. Neither striated columnar cells nor goblet cells stained with PNA-HRP conjugates. Glyco-conjugates of goblet cell mucins reacted with DBA and UEA I, but staining intensities varied in crypts and villi: positive goblet cells occurred preferentially in upper parts of the crypts and in villi. Striated columnar cells also exhibited variation in staining intensities, with binding of DBA and UEA I observed in the upper half of crypts and in villi, occurring predominantly along the brush border and in apical parts of the cells. Glyco-conjugates synthesized by Brunner's gland cells possessed a great variety of lectin reactivity with the lectins employed. Within a given histological section positive gland areas with different staining intensities beside negative cell populations might reflect different functional states.

Key words: Lectins – Glycoconjugates – Duodenal mucosa – Histology

The small intestine has an intensive digestive, absorptive and secretory function and commences at the duodenum. Its mucosa can be affected by a number of gastro-intestinal diseases. While the normal duodenal mucosa secretes neutral and acid glyco-conjugates, qualitative and quantitative changes will occur in disease states (Lev and Spicer 1965; Goldman and Ming 1968; Gad 1969a and b; Filipe and Fenger 1979; Morson and Dawson 1979). Yet little is known about changes in mucus secretion patterns. For

Offprint requests to: W.D. Kuhlmann at the above address

a comprehensive understanding of functional and structural changes in normal development and disease, a systematic analysis of cellular mucins is necessary.

With the introduction of peroxidase (HRP) labelled lectins well defined carbohydrate moieties in cells can be easily detected for the characterization of glyco-conjugate composition in organs. Thus, attempts have been made to localize carbohydrate residues in gastrointestinal mucosa cells by use of fluorescein, HRP, ferritin etc. labelled lectins at both light and electron microscopic levels (Etzler and Branstrator 1974; Freeman et al. 1980; Stoward et al. 1980; Suzuki et al. 1981; Sato and Spicer 1982; Boland et al. 1982). These studies were mainly performed on animal tissues and definite conclusions are not possible. Despite this, lectin-labelling is important for the study of carbohydrate composition of cell surface and intracellular glyco-conjugates, a prerequisite for functional and structural knowledge of mucins. To this aim, HRP conjugated lectins from *Dolichos biflorus* with specificity for N-acetyl-galactosamine (α -D-GalNAc), from *Arachis hypogaea* with specificity for D-galactose N-acetyl-galactosamine (β -D-Gal-(1-3)-D-GalNAc), from *Ulex europaeus* with specificity for L-fucose (α -L-Fucose) and from *Bandeiraea simplicifolia* with specificities for D-galactosyl (α -D-Gal) and N-acetyl-galactosamyl groups (α -D-GalNAc) were employed in a post-embedding technique for the localization of their respective sugar residues in paraffin sections from normal human duodenum.

Material and methods

Biochemicals. Peroxidase (HRP) conjugates of *Arachis hypogaea* agglutinin (PNA), *Dolichos biflorus* agglutinin (DBA), *Bandeiraea simplicifolia* agglutinin I (BSA I) and *Ulex europaeus* agglutinin I (UEA I) were obtained from Medac GmbH (Hamburg, FRG). The respective inhibitors, i.e. D-galactose, lactose and L-fucose were purchased from Merck (Darmstadt, FRG), and N-acetyl-D-galactosamine was obtained from Roth (Karlsruhe, FRG).

Tissues. Ten human duodenal mucosae of blood groups A, B, AB and 0 were obtained by surgery. From each duodenum, multiple samples were taken. Specimens were fixed in 99% ethanol - 1% acetic acid for 12-15 h at 0°-4° C, dehydrated in absolute ethanol, cleared in benzene and embedded in paraffin (Kuhlmann 1975).

Histology and lectin staining. Routine histology was performed on sections with H.E., PAS and Alcian blue at pH 2.5 (Pearse 1980).

For lectin staining, 5-7 μ m thick sections were mounted on acetone cleaned slides, deparaffinated in xylene and passed from absolute ethanol into phosphate-buffered saline (0.01 M phosphate pH 7.2 plus 0.15 M NaCl; PBS). Prior to incubation in lectin conjugates, endogenous peroxidases in tissue sections were irreversibly inhibited by treatment with 1% hydrogen peroxide in PBS for 1 h (Kuhlmann 1975). Slides were then washed in PBS and incubated with either of the above described HRP-labelled lectins (0.001-0.02 mg/ml PBS) for 24 h at 4° C (Kuhlmann et al. 1983). Unreacted conjugates were washed off by three successive washings for 5 min each in PBS. Peroxidase activity was finally revealed by incubation in 3,3'-diaminobenzidine tetrahydrochloride and H₂O₂ (Graham and Karnovsky 1966). After washings in PBS, sections were dehydrated and mounted under coverglass.

Controls. Specificity of lectin binding was controlled on serial sections by incubation as above in the HRP-labelled lectins which have been supplemented with either of the respective inhibi-

tors: 0.2 M D-galactose and 0.2 M lactose for PNA; 0.2 M D-galactose for BSA I; 0.2 M L-fucose for UEA I; 0.15 M N-acetyl-D-galactosamine for DBA. Each procedure was followed by washing in PBS and the enzyme substrate.

Results

All observations with the different types of duodenal mucosa cells are summarized in Table 1. With duodenal mucosa specimens of donor blood groups A, B, AB and 0, lectin staining patterns with DBA, PNA and UEA I did not merely reflect blood group reactivities. In contrast, BSA I reactivity corresponded with the presence of blood groups B and AB.

DBA reactivity

Striated columnar cells reacted negatively in 7 from 10 cases. In three cases, striated columnar cells showed positive reactions in apical and supranuclear cell areas as well as in the brush border. Goblet cells were negative in 6 cases, but positive DBA staining was observed in 4 cases. Goblet cells of villi and upper crypts stained more intensively than goblet cells in lower parts of the crypts in which unreactive goblet cells could also occur. In two cases, Brunner's gland cells did not react. In specimens from 8 patients, different positive staining reactivities were observed. In the latter preparations, non-reactive gland cells were found besides the DBA positive ones.

PNA reactivity

Neither striated columnar cells nor goblet cells stained with PNA. Positive PNA reactivity was observed in Brunner's gland cells beside negative gland cells of different number (Fig. 1). Within the same histological preparation, Brunner's gland cells exhibited both faint and strong staining intensities. Gland cells close to the lumen possessed reactions which were often stronger than gland cells of lobules deep in the duodenal submucosa. Also, PNA positive small-sized and single cells, flat or of triangular shape occurred

Table 1. Histological lectin bindings in normal human duodenum

Localization of lectins	DBA	PNA	UEA I	BSA I ^a
Columnar cells	mainly — ^b few +	—	+	—
Goblet cells	+ and —	—	+ and —	—
Brunner's gland cells	mainly + few —	mainly + few —	+	<i>blood group B, AB</i> mainly + and few — <i>blood group A, 0</i> —

^a In presence of 0.02 M D-GalNAc (see text)

^b Intensity of reactions: + positive; — negative; + and — positive as well as negative areas in a given histological section

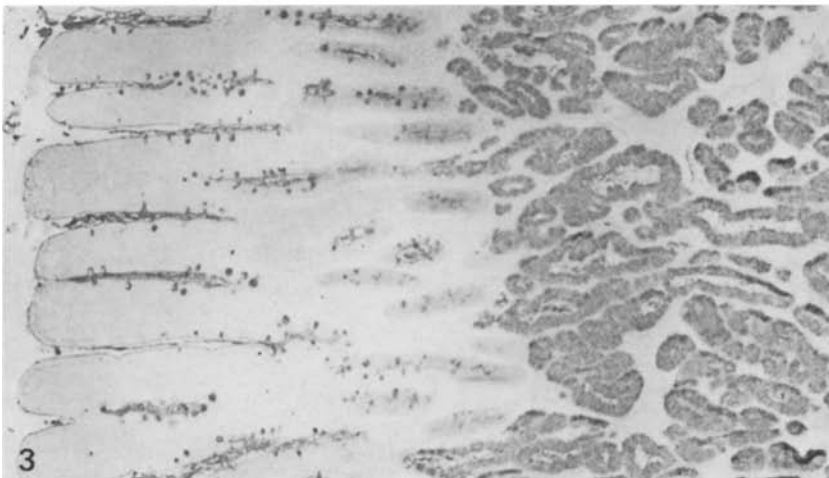
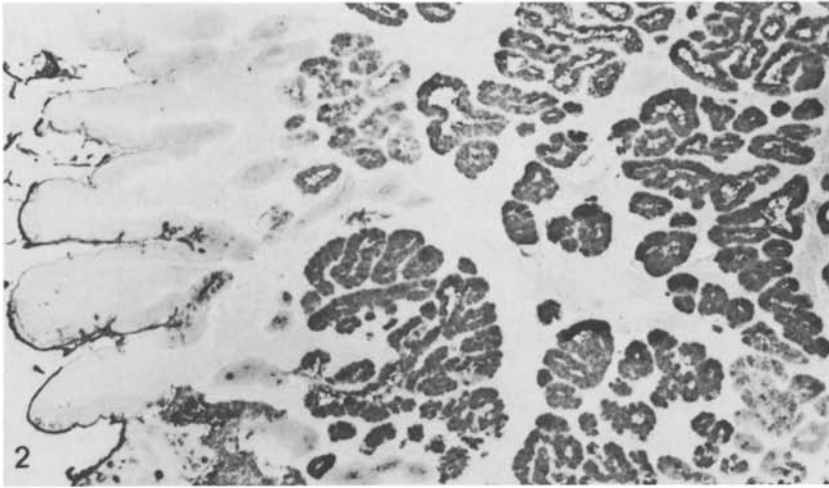
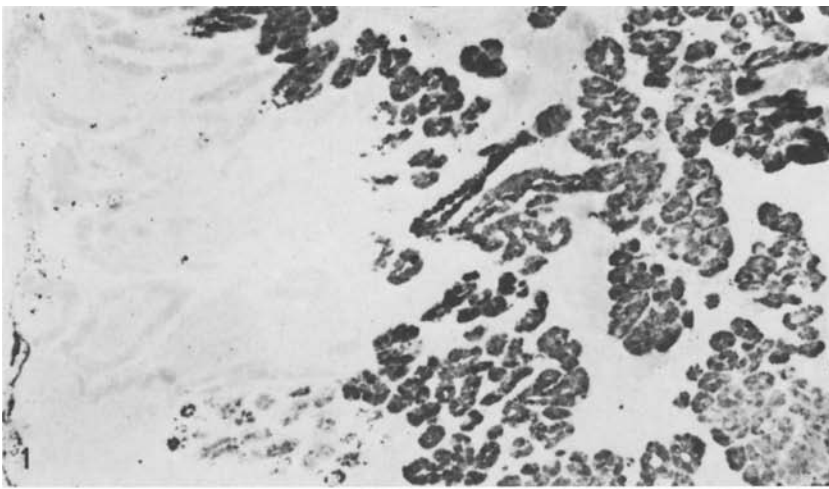


Fig. 1. PNA positivity of Brunner's glands. No staining in goblet cells and striated columnar cells. Original $\times 63$

Fig. 2. UEA I positivity of striated columnar cells with strong reaction of the brush border. Note only occasional positive goblet cells and clear-cut staining of Brunner's glands. Original $\times 63$

Fig. 3. UEA I positivity of Brunner's glands and numerous goblet cells. Original $\times 63$

between basement membrane and Brunner's glands. The origin of such cells remained unclear and they might be part of the diffuse endocrine cell system.

UEA I reactivity

Striated columnar cells were positive in all cases. Positive reactions were found in the upper half of the crypts and in villi. UEA I binding occurred predominantly along the brush border and also in the apical parts of the cells. Brunner's gland cells also reacted with UEA I. In 6 from 10 specimens, positive goblet cells were observed (Fig. 2 and 3). In some histological sections, positive and negative goblet cells were seen side by side. Positive goblet cells occurred preferentially in upper parts of the crypts and in villi than in the lower parts of the crypts. In specimens from 4 patients goblet cells did not stain at all.

BSA I reactivity

Striated columnar cells and goblet cells were negative in all cases. Brunner's gland cells mainly possessed positive reactivity; few negative cells were also found. Such positive reactions occurred only in tissue sections from donor blood group B and AB, whereas sections from donor blood group A and O were always negative.

Discussion

Several mucus glycoproteins from human and animal sources have been isolated and characterized, but few data are available for duodenal mucosa. Recently, Smits et al. (1982) isolated and partially characterized a duodenal glycoprotein of the rat. These authors demonstrated that the chemical composition of the purified glycoprotein is typical for mucin-type glycoproteins. These are generally macromolecules in which a peptide core is linked to oligosaccharide chains via glycosidic binding between serine or threonine and N-acetyl-galactosamine residues. Furthermore, oligosaccharide side chains consist of galactose, fucose, N-acetyl-glucosamine, N-acetyl-galactosamine and neuraminic acid.

In our study of duodenal glycoconjugates we have employed several carbohydrate specific lectins: (1) PNA which binds to terminal β -galactosyl and galactosamine sites, but which does not interact with either N-acetyl-galactosamine or 2-deoxy-galactose (Lotan et al. 1975); (2) DBA which has a specificity for terminal nonreducing alpha-N-acetyl-D-galactosamyl residues (Etzler and Kabat 1970); (3) BSA I is a tetrameric glycoprotein containing two types of subunits (A and B) from which 5 isolectins with different carbohydrate specificities are known. Previous studies have shown that the addition of 0.02 M D-GalNAc to the isolectin mixture is specific for alpha-D-galactopyranosyl groups (Murphy and Goldstein 1977); (4) UEA I with specificity for alpha-L-fucose (Matsumoto and Osawa 1969).

Lectin binding specificities are usually studied by agglutination tests with the use of various sugars as inhibitors. However, Stoward et al. (1980) observed unexplained discrepancy between agglutination tests and histological lectin stainings which raises the question as to the specificity of lectins as histochemical reagents. Hence, it remains to be clarified if agglutination tests are sufficient for the determination of lectin specificity.

Because gastrointestinal secretions may contain blood group antigens A, B and O (H) (Slocombe et al. 1980; Kapadia et al. 1981) their interaction with lectins must be reconciled. DBA reacts with blood group A, BSA I with blood group B and UEA I with blood group H. In our histological lectin studies we found that cellular stainings with PNA, DBA and UEA I were independent from the donor blood groups. Thus, the same staining patterns were observed in our material from normal human duodenal mucosae of blood groups A, B, AB and O. However, in the case of BSA I strong limitation of lectin binding to blood group B and AB was obvious. Hitherto, little is known on precise sequences of precursor oligosaccharide chains and the peripheral glycosylation patterns in human mucins so that further studies are necessary (Hounsell and Feizi 1982). These will include successive enzymatic digestions of tissue components by glycosidases. With these reservations in mind it is clear that our results are not for immediate use in routine diagnosis of gastrointestinal disease.

Two fundamental staining techniques for mucus glycoproteins in tissues have been widely employed: (a) periodic acid-Schiff reaction for the detection of neutral mucins; (b) cationic dyes at controlled pH for the discrimination of sialo- and sulphomucins, respectively (Lev and Spicer 1964; Spicer 1965). Combination of both procedures and further modifications are also described (Filipe 1979; Culling et al. 1981). The mechanism of lectin binding to specific sugars and steric effects of inner chain linkages are not yet clear, but we can assume that the four employed lectins are capable to bind to PAS positive carbohydrates and probably independent of accessible vicinal hydroxy groups. These occur in (a) terminal nonreducing residues, e.g. N-acetylneuraminic acid and L-fucose; (b) unbranched interior chain residues, e.g. D-galactose linked at C₂, C₄ or C₆ and N-acetyl-hexosamine linked at C₆; (c) branched interior chain residues, e.g. D-galactose linked as cis vicinal diols at C₂ and C₆ or as trans vicinal diols at C₄ and C₆ (Culling and Reid 1977).

Goblet cells

Duodenal goblet cells usually show reactivity with Alcian blue at pH 2.5 and with PAS. This indicates that goblet cells in normal duodenum contain neutral as well as acid mucins (N-acetylated sialomucins, while sulphomucins are absent). Because lectin stainings show quite heterogenous pictures, distinct differences in terminal carbohydrate structures of goblet cell glycoconjugates occur. While BSA I and PNA did not react at all, UEA I stained some of the goblet cells. This will most probably indicate either fucose residues in glyco-conjugates, whereas unreactivity either means absence or

sterically hindered fucose residues in their carbohydrate portions. Goblet cells of villi and upper parts of the crypts surprisingly stained more intensely than the goblet cells in lower parts of the crypts. Similar stainings occurred with DBA. Hence, fucose and GalNAc must be added to mucins in the course of goblet cell maturation. Our observations are in agreement with previous high iron diamine-Alcian blue stainings by Filipe and Fenger (1979) who demonstrated in normal duodenum a gradual change of mucin composition from crypts (neutral mucins) to the villi (mature goblet cells) where sialomucins predominate.

Striated cells

The microvilli of intestinal epithelial cells are usually covered with PAS positive material, and evidence exists that the latter is synthesized by the cells and is an integral part representing the glycocalix (Ito 1969). In the present study such PAS reacting components were stained, and binding properties for DBA and UEA I occurred in the brush border whereas no PNA binding was demonstrated. Moreover, UEA I and DBA positive reactions were observed in PAS negative apical areas of these cells. With respect to the histological distribution of UEA I reactivities, a distinct difference in enterocytes' carbohydrate composition was obvious: columnar cells in villi were predominantly positive while those in the crypts remained negative. This observation is in accordance with findings of Etzler and Branstrator (1974) who found terminal nonreducing β -D-galactosyl, α -L-fucosyl and β -N-acetylglucosaminyl and/or sialic acid residues in the glycocalix of rat intestinal enterocytes. These authors also detected different reactivities of microvilli of crypt cells and villi. It was suggested that crypt cells differentiate and move upwards to the villi by which process terminal carbohydrate residues will be changed by chemical or enzymatic procedures. Finally, supranuclear areas (probably Golgi zones) of numerous enterocytes possessed affinities for DBA and UEA I. Thus, nascent carbohydrates in glyco-conjugates or the presence of Golgi bound glycosyl transferases (which are also glycoproteins) might be stained. The latter are known to add hexoses to growing oligosaccharide side chains (Weiser and Wilson 1981).

Brunner's glands

In human duodenum, Brunner's glands show intense PAS reactivity and do not stain with cationic dyes. Glyco-conjugates secreted by these glands are generally accepted to contain only neutral PAS positive carbohydrates (Lev and Spicer 1965; Sheahan and Jervis 1976; Filipe 1979). In the present lectin study, UEA I stained homogenously the bulk of Brunner's glands confirming the results of Gottschalk (1963) who described fucose to be the terminal carbohydrate residue in neutral mucins. However, Lev and Spicer (1965) reported on failure of fucosidase to decrease PAS stainability so that other sugar residues (as those described above) in subterminal position will be able to lead to PAS reactivity.

Apart from fucose, Brunner's glands contain further terminal carbohydrate residues (e.g. alpha, beta-galactosyl groups and N-acetyl-galactosamine groups) which react with BSA I, PNA and DBA, respectively. If the staining of Brunner's glands with these lectins is not due to a mixture of different terminal carbohydrate residues, then a possible explanation would be that lectin staining is not limited to terminal carbohydrate residues. Within a given histological section, inhomogenous reactions with DBA, BSA I and PNA were found: (a) positive gland areas with different staining intensities; (b) negative cell populations. These observations express significant differences in Brunner's glands reflecting different functional states. It is suggested that double staining experiments on the same histological sections will demonstrate if coincidence exists.

Finally, we are still in a descriptive phase in our experiments. Availability and application of further lectins with other distinct specificities will enhance, in the near future, the interpretation of normal and diseased states of human gastrointestinal glyco-conjugate synthesis. Histological lectin binding studies will give more information on the structural composition of cellular oligosaccharide moieties in health and disease.

Acknowledgement. This study was supported by the Deutsche Forschungsgemeinschaft (Ku 257/5-2 and Ku 257/6-3) Bonn, FRG.

References

- Boland CR, Montgomery CK, Kim YS (1982) Alterations in human colonic mucin occurring with cellular differentiation and malignant transformation. *Proc Natl Acad Sci (USA)* 79:2051–2055
- Culling CFA, Reid PE (1977) The apparent failure of sodium borohydride reduction to block further PAS reactivity in rat epithelial mucins. *Histochem J* 9:781–785
- Culling CFA, Reid PE, Dunn WL, Freeman HJ (1981) The relevance of the histochemistry of colonic mucins based upon their PAS reactivity. *Histochem J* 13:889–903
- Etzler ME, Kabat EA (1970) Purification and characterization of a lectin (plant hemagglutinin) with blood group A specificity from *Dolichos biflorus*. *Biochemistry* 9:869–877
- Etzler ME, Branstrator ML (1974) Differential localization of cell surface and secretory components in rat intestinal epithelium by use of lectins. *J Cell Biol* 62:329–343
- Filipe MI (1979) Mucins in the human gastrointestinal epithelium: a review. *Invest Cell Pathol* 2:195–216
- Filipe MI, Fenger C (1979) Histochemical characteristics of mucins in the small intestine. A comparative study of normal mucosa, benign epithelial tumours and carcinoma. *Histochem J* 11:277–287
- Freeman HJ, Lotan R, Kim YS (1980) Application of lectins for detection of goblet cell glycoconjugate differences in proximal and distal colon of the rat. *Lab Invest* 42:405–412
- Gad A (1979a) A histochemical study of human alimentary tract mucosubstances in health and disease. I. Normal and tumours. *Br J Cancer* 23:52–63
- Gad A (1979b) A histochemical study of human alimentary tract mucosubstances in health and disease. II. Inflammatory conditions. *Br J Cancer* 23:64–68
- Goldman H, Ming SC (1968) Mucins in normal and neoplastic gastrointestinal epithelium. *Arch Pathol* 85:580–586
- Gottschalk A (1963) The basic structure of glycoproteins and problems of their chemical and physicochemical analysis. *Ann NY Acad Sci* 106:168–176
- Graham RC, Karnovsky MJ (1966) The early stages of absorption of injected horseradish peroxidase in the proximal tubules of mouse kidney: ultrastructural cytochemistry by a new technique. *J Histochem Cytochem* 14:291–302

- Hounsell EF, Feizi T (1982) Gastrointestinal mucins. Structures and antigenicities of their carbohydrate chains in health and disease. *Med Biol* 60:227–236
- Ito S (1969) Structure and function of the glycocalyx. *Fed Proc* 28:12–25
- Kapadia A, Feizi T, Jewell D, Keeling J, Slavin G (1981) Immunocytochemical studies of blood group A, H, I and i antigens in gastric mucosae of infants with normal gastric histology and of patients with gastric carcinoma and chronic benign peptic ulceration. *J Clin Pathol* 34:320–37
- Kuhlmann WD (1975) Purification of mouse alpha₁-fetoprotein and preparation of specific peroxidase conjugates for its cellular localization. *Histochemistry* 44:155–167
- Kuhlmann WD, Peschke P, Wurster K (1983) Lectin-peroxidase conjugates in histopathology of gastrointestinal mucosa. *Virchows Arch [Pathol Anat]* 398:319–328
- Lev R, Spicer SS (1964) Specific staining of sulphate groups with Alcian blue at low pH. *J Histochem Cytochem* 12:309
- Lev R, Spicer SS (1965) A histochemical comparison of human epithelial mucins in normal and in hypersecretory states including pancreatic cystic fibrosis. *Am J Pathol* 46:23–48
- Lotan R, Skutelsky E, Danon D, Sharon N (1975) The purification, composition, and specificity of the Anti-T lectin from peanut (*Arachis hypogaea*). *J Biol Chem* 250:8518–8523
- Matsumoto I, Osawa T (1969) Purification and characterization of an Anti-H(0) phytohemagglutinin of *Ulex europaeus*. *Biochim Biophys Acta* 194:180–189
- Morson BC, Dawson IMP (1979) *Gastrointestinal Pathology*. Blackwell, Oxford London
- Murphy LA, Goldstein IJ (1977) Five α -D-Galactopyranosyl-binding isolectins from *Bandeiraea simplicifolia* seeds. *J Biol Chem* 252:4739–4742
- Pearse AGE (1980) *Histochemistry. Theoretical and Applied*. Churchill-Livingstone, London
- Sato A, Spicer SS (1982) Ultrastructural visualization of galactosyl residues in various alimentary epithelial cells with the peanut lectin-horseradish peroxidase procedure. *Histochemistry* 73:607–624
- Sheahan DG, Jervis HR (1976) Comparative histochemistry of gastrointestinal mucosubstances. *Am J Anat* 146:103–132
- Slocombe GW, Berry CL, Swettenham KV (1980) The variability of blood group antigens in gastric carcinoma as demonstrated by the immunoperoxidase technique. *Virchows Arch [Pathol Anat]* 387:289–300
- Smits HL, Van Kerkhof JM, Kramer MF (1982) Isolation and partial characterization of rat duodenal-gland (Brunner's-gland) mucus glycoprotein. *Biochem J* 203:779–785
- Spicer SS (1965) Diamine methods for differentiating mucosubstances histochemically. *J Histochem Cytochem* 13:211–234
- Stoward PJ, Spicer SS, Miller RL (1980) Histochemical reactivity of peanut lectin-horseradish peroxidase conjugate. *J Histochem Cytochem* 28:979–990
- Suzuki S, Tsuyama S, Suganuma T, Yamamoto N, Murata F (1981) Postembedding staining of Brunner's gland with lectin-ferritin conjugates. *J Histochem Cytochem* 29:946–952
- Weiser MM, Wilson JR (1981) Serum levels of glycosyltransferases and related glycoproteins as indicators of cancer: biological and clinical implications. *CRC Crit Rev Clin Lab Sci* 14:189–239